Trauma in Eyes

Disclaimer

COVID-19 note

The Royal Australian and New Zealand College of Ophthalmologists (RANZCO) and The Royal Australian College of General Practitioners (RACGP) have made recommendations regarding eye examination during the COVID-19 pandemic. See RANZCO – COVID-19: Practical Guidance for General Practitioners Performing Eye Examinations.

Last updated: 18 May 2020

Contents

Red Flags

- History suggestive of penetrating injury
- Distorted pupil
- Altered vision associated with trauma
- Alkali or strong acid burns

Assessment

Assessment

1. Take a history to determine likelihood of corneal damage or penetrating eye injury:
   - Foreign material involved e.g., glass, cement or lime, ***caustic chemicals or acid***

Chemical burn: tissue gets coagulated, here due to anhydrous ammonia, with the conjunctiva and edge of cornea affected.
Copyright 2018 EyeRounds.org

   - Possible explosion
   - Object thrown or forced into the eye, sharp edged, or high energy
   - Hammering metal on metal – high velocity metal fragment

2. Examination:
   - If high suspicion of penetrating eye injury do not examine, as it may cause further injury.
   - Check for ***signs of a penetrating eye injury.***

Signs of penetrating eye injury

- *Subconjunctival haemorrhage, which can hide a penetrating eye injury*
- *Full thickness scleral or corneal laceration*
- *Abnormal iris e.g., tear-drop shaped*
- *Unusual red reflex*
- *If no clear symptoms or signs, but history is suspicious, consider:*
  - ***Seidel test.***

Seidel test

- *Apply 2% fluorescein drops directly over the potential site of perforation while observing the site under the blue light of the slit lamp.*

- *If a perforation and leak exist, the fluorescein is diluted by the aqueous to appear as a dilute green stream within the dark orange dye.*

See Root Atlas – Positive Seidel test [video, 53 seconds]

- X-ray of orbits, especially if metallic foreign body is suspected.

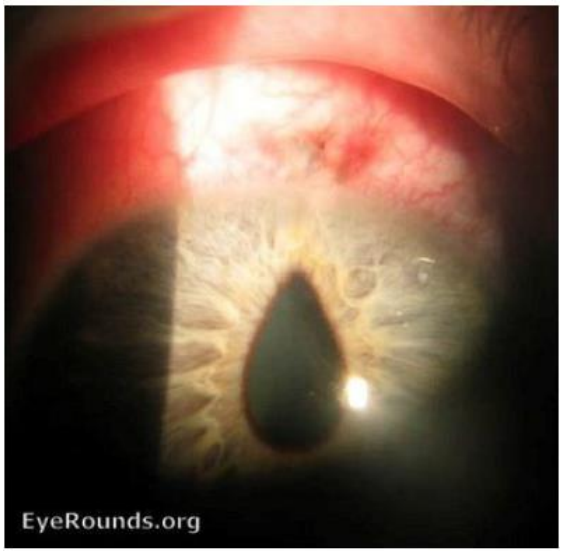

"Peaked pupil" seen in penetrating eye injury.
Copyright 2018 EyeRounds.org

➢ Check ***visual acuity.***

Visual acuity

1. *Ask if the patient has distance glasses with them, and if either eye has had known poor vision i.e., a lazy eye.*
2. *Test their distance vision in each eye, while wearing glasses, using a 3 or 4 m chart.*
3. *Check each eye separately, with distance glasses if worn.*
4. *If acuity is subnormal, check with a pinhole.*
5. *If vision improves with a pinhole, and no cataract is present, then the patient requires a review of their glasses.*
6. *If unable to read any letters on chart, assess the following in descending order:*
   - *Finger counting*
   - *Hand movements*
   - *Light perception*
7. *Test near vision while patient is wearing reading glasses.*

➢ Examine the cornea:

- Look for corneal foreign body if indicated from history (black spot or rounded protrusion on cornea).
- Look for ***hyphaema*** or ***hypopyon.***

Hypopyon

- *Inflammatory cells in front of iris*
- *Not usually present in the acute setting, however, may be present be seen in delayed presentation*

Hyphaema

- *Blood level in front of iris.*
- *A hyphaema is blood in the anterior chamber. Sometimes it may just be a haze, with red blood cells only visible under a slit lamp.*
- *Exclude globe rupture with a careful external and periocular eye exam.*

Hyphaema - blood in the front (anterior) chamber of the eye.
Copyright 2018 EyeRounds.org

- Assess pupil shape, symmetry, and reaction.
- Look for corneal abrasions – check cornea clear, iris details easily visible, stains with fluorescein, vision better with pinhole.
- Check red reflex – poor quality or black indicates hyphaema and sometimes lens damage or vitreous haemorrhage.
- Perform fundoscopy.

➢ ***Lid lacerations*** – look for deep cuts that may indicate penetration into the orbit and for full thickness lacerations across the lid margin.

➢ ***Child with eye trauma***

Child with eye trauma

- *History suggestive of direct trauma*

- *Look for ecchymosis, lacerations, punctures, subconjunctival haemorrhage, abnormal pupil shape e.g., tear drop*
- *Orbital blow out fracture in child may occur in normal appearing eye. There may be muscle entrapment with reduced eye movements and oculo-cardiac reflex with symptoms of nausea and vomiting on attempted eye movements*

3. If significant blunt trauma, consider other associated injuries:
   - ***Retrobulbar haemorrhage***

Retrobulbar haemorrhage

- *This may occur with trauma or surgery to the eye or orbit.*
- *Symptoms include pain and decreased vision.*
- *Signs:*
  - *Reduced visual acuity*
  - *Relative afferent pupillary defect*
  - *Diffuse subconjunctival haemorrhage*
  - *Tight eyelids*
  - *Proptosis, with resistance to retropulsion*

- ***Orbital wall "blow-out" fracture***

Orbital wall "blow-out" fracture

- *Usually caused by blunt trauma e.g., a punch, squash ball.*
- *Clinical features include:*
  - *pain, especially with vertical eye movement.*
  - *diplopia.*
  - *eyelid swelling and crepitus after blowing nose.*
  - *hyphaema.*
  - *restricted eye movements.*
  - *decreased sensation in distribution of infraorbital nerve.*

- *Orbital blow out fracture in a child may occur in a normal appearing eye. There may be muscle entrapment with reduced eye movements, and oculo-cardiac reflex with symptoms of nausea and vomiting on attempted eye movements.*

Management

1. Refer for immediate ophthalmology assessment if:
   - suspected ***penetrating injury.***

Penetrating injury

- *To prevent further trauma do not perform any examination of the eye.*
- *Do not apply any topical medication, including anaesthetic drops, as the preservatives can damage internal structures.*
- *Cover the eye with a shield (a shallow plastic container taped over the eye) not a pad.*
- *Give pain relief and antiemetics.*
- *Check tetanus immunisation status.*
- *Keep nil by mouth.*

- *If there will be any delay in specialist assessment, obtain ophthalmology advice regarding antibiotics.*

- ***retrobulbar haemorrhage.***

- ***hyphaema*** or hypopyon.

  Hyphaema
  - *Arrange immediate ophthalmology assessment, as there is a 50% incidence of secondary haemorrhage and a 7% incidence of glaucoma.*
  - *Exclude globe rupture with a careful external and periocular eye exam.*
  - *Have the patient lie down with head up at 30° and moved by stretcher or wheelchair.*
  - *Ensure patient does not drive or go home.*

- reduced visual acuity.
- abnormal pupil response.
- flashes and floaters.
- ***complex lid lacerations.***

  Complex lid lacerations
  - *Involvement of full thickness of the lid margin*
  - *Involvement of lacrimal duct or canalicular system*
  - *Involvement of medial canthus*

- ***child with clinical features requiring acute assessment –*** if review will be within 6 hours, ensure child remains nil by mouth.

  Clinical features requiring immediate referral or admission in children
  - *Obviously abnormal eye e.g., tear-drop shaped pupil.*
  - *History suggesting direct trauma.*
  - *Child distressed and completely unable to be examined in the setting of lid ecchymosis, lacerations, punctures, or subconjunctival haemorrhage.*

2. Manage acid or alkali ***chemical burn.***

   Chemical burn
   Emergency management:
   - *Instil topical anaesthetic, e.g., oxybuprocaine.*
   - *Lie the patient on a bed holding the lids open with a gloved finger.*
   - *Use Ringer's/Hartmann's solution, N/saline (0.9%) or sterile water for irrigation via 20 mL syringe or IV fluid bag with giving set and allowed to drip or flush into eye.*
   - *Consider use of Morgan's lens (sterile plastic device connected to tubing that fits over the eye and allows copious irrigation of the eye) after the first litre has been manually irrigated. Give more topical anaesthetic and then carefully insert the device if available.*[1]
   - *Severe burns may require irrigation for over 30 minutes.*
   - *Evert the eyelid to clear any foreign material with a moist cotton bud.*
   - *Provide analgesia, including further topical anaesthetic as required.*
   - *Obtain the chemical name, composition, and type, e.g. liquid or powder.*

- *After irrigation examine the eye for:*
  - *focal areas of conjunctival chemosis, hyperaemia, or haemorrhages.*
  - *corneal defects, e.g. superficial spots (punctate keratitis), areas of epithelial sloughing.*

Further care and follow-up:

- *If **alkali burn**, seek immediate ophthalmology assessment.*
- *If **acid burn** and:*
  - *corneal epithelial defect is 3 mm or less and cornea is otherwise transparent, provide chloramphenicol ointment and **patch the eye**. Seek ophthalmology advice.*

    Padding the eye

    1. *Use a double pad technique as the lid must be held down firmly.*
    2. *Ask the patient to keep both eyes gently closed until finished.*
    3. *Fold the first pad in half and secure the second over the top. Ensure the medial and lateral parts of the pad are pushed down firmly onto the eyelid.*
    4. *Use two strips of 2 cm wide paper tape long enough to reach from the middle of the forehead towards the ear.*

- *corneal epithelial defect is larger than 3 mm or the cornea is hazy, refer for immediate ophthalmology assessment.*

3. If difficulty with interpretation of clinical eye trauma signs seek ophthalmology advice.

4. If suspected orbital wall fracture:
   - if high suspicion for fracture, refer for immediate oral maxillofacial surgery assessment for CT of facial bones.
   - if low suspicion of fracture, consider initial screen with CT of facial bones.
   - if unsure, seek oral maxillofacial surgery advice.

5. Manage corneal foreign body (including rust rings).

6. Consider suture lid lacerations unless they involve:
   - full thickness of the lid margin.
   - the medial canthus or lacrimal/canalicular system.

Referral

- Refer for immediate ophthalmology assessment if:
  - suspected penetrating eye injury.
  - retrobulbar haemorrhage.
  - hyphaema or hypopyon.
  - reduced visual acuity
  - abnormal pupil response
  - flashes and floaters
  - complex lid lacerations
  - alkali burn.
  - acid burn with corneal epithelial defect over 3 mm or hazy cornea.

- ***child with clinical features requiring acute assessment.***

- Seek ophthalmology advice if:
  - acid burn with corneal epithelial defect 3 mm or less and cornea is transparent.
  - difficulty with interpretation of clinical eye trauma signs.

- If orbital wall fracture, refer for immediate oral maxillofacial surgery assessment.
- If unsure of orbital wall fracture, seek oral maxillofacial surgery advice.

Information

For health professionals

Further information

- GP Eyes – Penetrating Eye Injuries [subscription required]
- New South Wales Department of Health – Eye Emergency Manual: Common Emergencies

References

1. Emergency Care Institute New South Wales. NSW: Agency for Clinical Innovation; Eye Trauma - Chemical Burns. 19 Sept 2017.

Disclaimer

Last updated: June 2020